


## CASE REPORT

# A case of an Infant with SARS-CoV-2 hepatitis early after liver transplantation

Nicole Heinz<sup>1</sup> | Adam Griesemer<sup>1</sup>  | Joanna Kinney<sup>2</sup> | Jennifer Vittorio<sup>3</sup> |  
 Stephen M. Lagana<sup>4</sup> | Dana Goldner<sup>3</sup> | Monica Velasco<sup>1</sup> | Tomoaki Kato<sup>1</sup> |  
 Steven Lobritto<sup>3</sup> | Mercedes Martinez<sup>3</sup> 

<sup>1</sup>Department of Surgery, Vagelos College of Physician and Surgeons, Columbia University, New York, NY, USA

<sup>2</sup>Department of Pediatrics, NewYork Presbyterian Hospital, New York, NY, USA

<sup>3</sup>Department of Pediatrics, Vagelos College of Physician and Surgeons, Columbia University, New York, NY, USA

<sup>4</sup>Department of Pathology, Vagelos College of Physician and Surgeons, Columbia University, New York, NY, USA

## Correspondence

Mercedes Martinez, Department of Pediatrics, Vagelos College of Physician and Surgeons, Columbia University, 622 West 168th street, PH17 East Room 105B, New York, NY 10032.

Email: mm2479@cumc.columbia.edu

## Abstract

We present a case of a pediatric liver transplant recipient diagnosed with severe acute respiratory syndrome coronavirus 2 (SARS-CoV-2) infection four days after receiving a living donor liver allograft from her mother. The recipient was a 6-month-old with end-stage liver disease due to biliary atresia and failed Kasai. The infant had an uncomplicated implantation, excellent graft function and down-trending liver enzymes until developing fevers, diarrhea, and moderate respiratory distress requiring non-invasive respiratory support. SARS-CoV-2 testing (nasal swab Polymerase Chain Reaction) was positive on post-operative day (POD) 4. Liver enzymes peaked ~1000 U/L (5-fold higher than the previous day) on POD 6. Histology demonstrated a mixed picture of moderate acute hepatitis and classical elements of mild to moderate acute cellular rejection. Her hepatitis and respiratory symptoms improved coincident with completing treatment with hydroxychloroquine, reduced immunosuppression, and intravenous gamma globulin (IVIG).

## KEYWORDS

acute rejection, Hepatitis, SARS-CoV-2, SARS-CoV-2 hepatitis

## 1 | INTRODUCTION

Rapidly evolving literature describes case reports of the severe acute respiratory syndrome coronavirus 2 (SARS-CoV-2), and the myriad of clinical manifestations of this infection known as coronavirus disease 2019.<sup>1</sup> Few studies have clinically characterized the disease in the pediatric population<sup>2</sup> and none in immunosuppressed children. At least one clinical report suggests that immunosuppressed patients are not at increased risk for severe disease or mortality.<sup>3</sup> In this report, we describe the clinical course and treatment of a 6-month-old female who underwent living related donor liver transplant (LT) from her mother and tested positive for SARS-CoV-2 four days post-operatively. In the interest of rapidly circulating information to our community, we previously published a partial description of this case focused on histopathology.<sup>4</sup> For the benefit of a wider

pediatric transplant audience, we hope to provide more detailed information regarding the clinical course as it relates to available treatment and immunosuppression management.

## 2 | CASE REPORT

The recipient is a 6-month-old female with end-stage liver disease due to biliary atresia. She underwent a left lateral segment living related LT from her mother on March 17, 2020. Her calculated pediatric end-stage liver disease score was 25 at the time of transplant. On the day of the surgery, the epidemic was just starting with only 6129 total cases and 171 total deaths reported in the USA<sup>5</sup> and 923 cases and 10 deaths in New York City.<sup>6</sup> The infant was quite ill at the time of transplant with progressive liver dysfunction, and the case

was considered an urgent procedure. The team decision to proceed with the transplant contemplated the rate of progression of chronic liver failure, the risk of patient mortality before the epidemic abated, the perceived lower risk at the onset of the epidemic compared to the weeks/months ahead and the fact that neither the donor nor recipient demonstrated signs or symptoms of SARS-CoV-2 infection. There were no surgical complications, and mechanical ventilation was discontinued on post-operative day (POD) 1. She received our standard immunosuppression protocol with steroid induction and triple weight-based maintenance medications (see Table 1).

On POD 3, the donor developed transient sore throat and cough. She did not have fever, shortness of breath or desaturations. However, she tested positive for SARS-CoV-2 via nasopharyngeal (NP) polymerase chain reaction (PCR) on POD 4.

On POD 4, the recipient was noted to have nasal congestion and diarrhea. Given the donor's positive testing, the recipient was also assayed by nasopharyngeal sample for SARS-CoV-2 PCR. While awaiting test results, the recipient developed low-grade fevers and increased work of breathing; her oxygenation saturation was 99% on room air. Chest radiograph demonstrated patchy bilateral lung opacities and a large gastric air bubble. She was transferred to the pediatric intensive care unit, placed on continuous positive airway pressure (CPAP) ventilation for 12 hours with positive end expiratory pressure (PEEP) between 5 and 6 cm H<sub>2</sub>O. A nasogastric sump tube was placed for gastric decompression leading to improved respiratory symptoms and permitted weaning off CPAP. Tacrolimus trough on the morning of POD 4 was supratherapeutic (16 ng/dL, goal ~8) so

2 consecutive doses were held (Table 1, Figure 1). Given the clinical respiratory decompensation, the evening dose of mycophenolate mofetil (MMF) was held but was restarted the following morning after clinical improvement. A 5-day course of hydroxychloroquine at 7.5 mg/kg/dose was started immediately after confirming SARS-CoV-2 infection on POD 4. Daily WBC count persisted above 15.9 ×10<sup>3</sup>/μL (lymphocytes ~45%) and QTc intervals remained within expected limits during hydroxychloroquine therapy.

Between POD 5 and 6 the recipient became persistently febrile for 20 hours despite treatment with acetaminophen, but her respiratory symptoms did not worsen. She was started on empiric piperacillin-tazobactam after collecting urine and blood samples for culture with unrevealing results. Laboratory tests were notable for erythrocyte sedimentation rate 4 mm/h (0-20 mm/h), creatinine kinase 80 U/L (40-308 U/L), troponin T high sensitivity 16 ng/L (<14 ng/L), lactate dehydrogenase 1206 U/L (190-420 U/L), ferritin 1090 ng/mL (13-150 ng/mL), and procalcitonin 0.18 ng/mL (< = 0.08 ng/mL).

Gastrointestinal PCR and Clostridium difficile studies sent to evaluate persistent diarrhea were negative. In addition to her 3 immunosuppressive agents, the patient received additional prophylactic medications as per center protocol (oral aspirin, enoxaparin, valganciclovir, nystatin, sulfamethoxazole/trimethoprim, and ursodiol).

Liver enzymes had been trending downward as expected since the LT; however, on POD 6, there was a sudden significant elevation of liver enzymes (see Table 1, Figure 2). A liver ultrasound with Doppler showed patent hepatic vasculature and no intra-abdominal

**TABLE 1** Demographics and clinical data

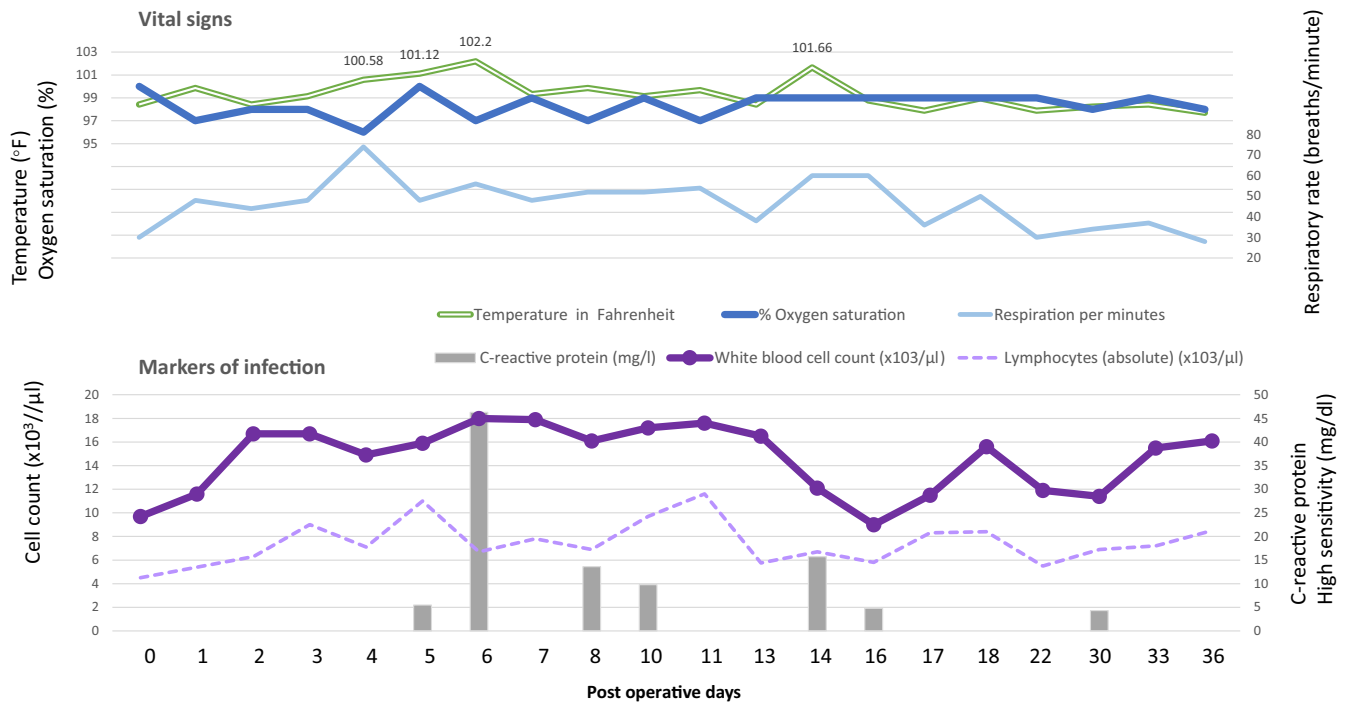
Variables	POD Timeline	0	1	2	3 <sup>a</sup>	4 <sup>b</sup>	5	6	7 <sup>††</sup>	8 <sup>b</sup>	10	11	13	14	16	17 <sup>††</sup>	18	22	30 <sup>††</sup>	33	36
<b>Vital Signs</b>																					
Maximum temperature (°C)		36.9	37.7	36.9	37.3	<b>38.1</b>	<b>38.4</b>	<b>39</b>	37.4	37.7	37.3	37.6	36.9	<b>38.7</b>	37.1	36.6	37.2	36.6	36.8	36.9	36.5
Peak respiratory rate		30	48	44	48	74	48	56	48	52	52	54	38	60	60	36	50	30	34	37	28
Lowest oxygen saturation		100	97	98	98	96	100	97	99	97	99	97	99	99	99	99	99	99	98	99	98
<b>Laboratory Values</b>																					
Aspartate Aminotransferase (U/L)		776	394	236	98	66	163	<b>908</b>	<b>606</b>	468	645	344	122	118	285	<b>515</b>	250	59	<b>354</b>	111	59
Alanine Aminotransferase (U/L)		396	373	347	231	172	215	<b>980</b>	<b>979</b>	945	1215	954	506	381	396	<b>604</b>	483	133	<b>512</b>	251	151
Alkaline phosphatase (U/L)		342	413	380	299	301	268	248	270	338	493	622	664	704	799	794	788	695	962	979	760
Gammaglutamyl transferase (U/L)		174	167	143	119	110	97	110	158	194	377	493	371	388	504	576	472	320	656	535	590
Bilirubin, total (mg/dl)		3.6	3.2	2.7	2	1.8	1.4	1.1	1.1	0.1	0.9	0.9	0.7	0.6	0.6	0.6	0.5	0.4	0.8	0.6	0.4
Bilirubin, direct (mg/dl)		2.5	2.1	1.6	1.3	1.2	0.9	0.7	0.7	0.6	0.6			0.4	0.4	0.4	0.3	0.2	0.7	0.4	0.3
Bilirubin, indirect (mg/dl)		1.1	1.1	1.1	0.7	0.6	0.5	0.4	0.4	0.4	0.3			0.2	0.2	0.2	0.2	0.2	0.1	0.2	0.1
White blood cell count (X10 <sup>3</sup> /μl)		9.7	11.6	16.7	16.7	14.9	15.9	18.0	17.9	16.1	17.2	17.6	16.5	12.1	9.0	11.5	15.6	11.9	11.4	15.5	16.1
Lymphocytes (absolute) (X10 <sup>3</sup> /μl)		4.5	5.4	6.3	9.0	7.1	11.0	6.7	7.8	6.9	9.7	11.6	5.75	6.7	5.8	8.3	8.4	5.5	6.9	7.2	8.5
C-reactive protein, high sensitivity (mg/l)							5.5	<b>46.3</b>		<b>13.6</b>	9.8			<b>15.7</b>	4.8				4.3		
<b>Medications</b>																					
Methylprednisolone (mg/kg/day)		10	2	1.6	1.2			1	5	2	1	0.5							10		
Prednisolone (mg/kg/day)						1.2	0.6	0.6	0.6	0.4			0.6	0.6	0.6	0.6	0.6	0.6		2	1.5
Tacrolimus level (μg/mL)				2.4	10	<b>16.6</b>	8.3	3.4	7.1	5.2	13.6	8.1	3.8	4.1	5.4	8.1	11.1	7.2	5.7	9.8	9.1
Mycophenolate Mofetil (15mg/kg/dose) BID		X	X	X	X	X	X	X	X	X	0	0	0	0	0	0	0	0	X	X	X
Hydroxychloroquine (7.5 mg/kg)						X	X	X	X	X											

Note: Black bold line: divide clinical information before and after COVID-19 diagnosis on POD 4.

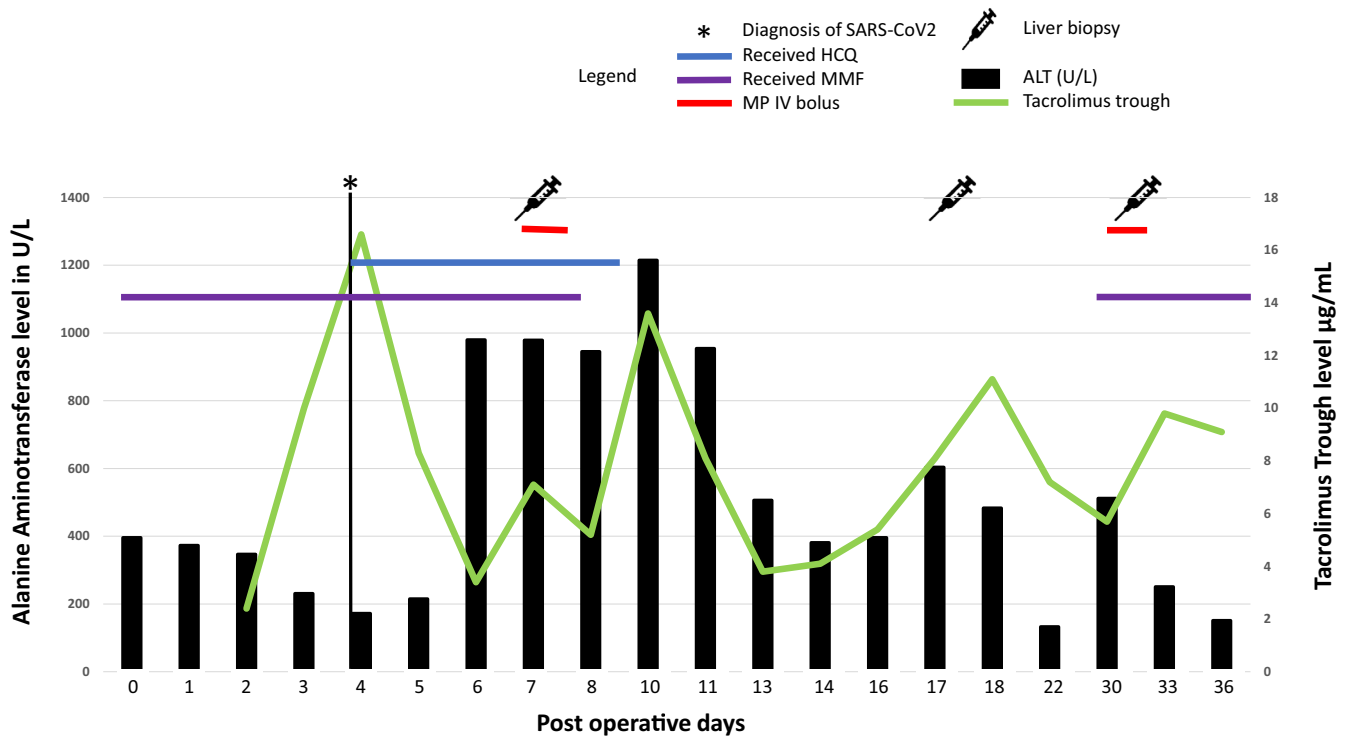
<sup>a</sup>Day 3: Donor tested positive for COVID-19. Patient began to show symptoms of cough and increased work of breathing.

<sup>b</sup>Day 4, 8: Patient required respiratory non-invasive support continuous positive airway pressure.

<sup>c</sup>Day 7, 17, 30: Patient underwent percutaneous liver biopsy. POD: post-operative day.



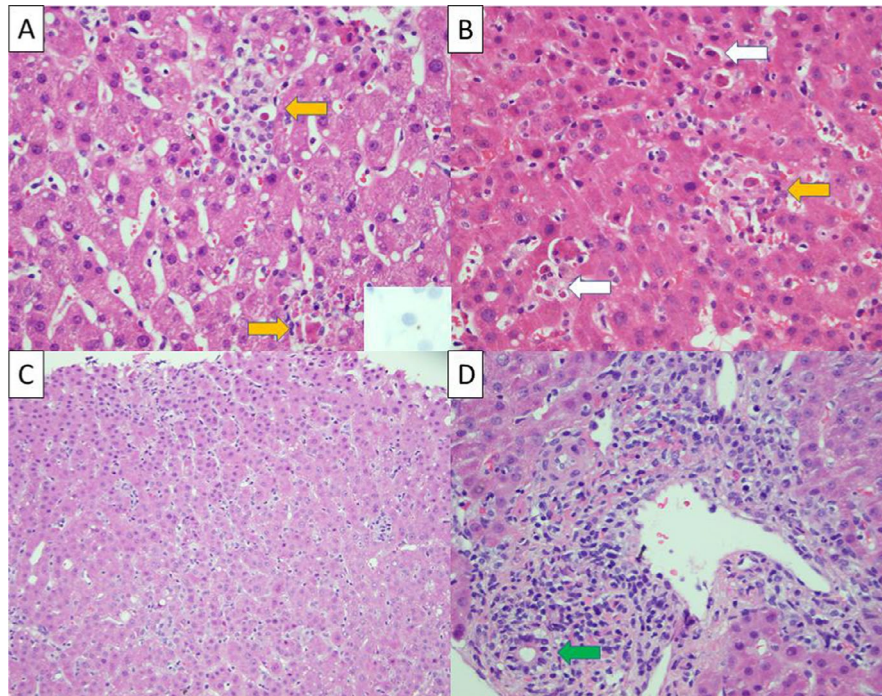
**FIGURE 1** Schematic representation of the most relevant vital signs values (upper panel), and laboratory test results over time (lower panel)



**FIGURE 2** Schematic representation of the most relevant clinical, laboratory, and therapeutics information related to the hepatitis flares. ALT: Alanine Aminotransferase, HCQ: hydroxychloroquine, MMF: Mycophenolate Mofetil, MP: Methylprednisolone, SARS-CoV-2: severe acute respiratory syndrome coronavirus 2 (SARS-CoV-2), IV: intravenous

collections. A liver biopsy performed on POD 7 demonstrated mixed portal inflammation (lymphocyte predominant with appreciable eosinophils) in most portal tracts with lymphocytic cholangitis and

mild portal venulitis. These changes were attributed to moderate acute cellular rejection (Banff 5). Moderate lobular hepatitis was also present, characterized by prominent foci of necroinflammation



**FIGURE 3** Initial allograft biopsy (Panel A) showing prominent foci of necroinflammation consisting of lymphocytes and apoptotic hepatocytes (yellow arrows) in nearly all lobules (H&E 400X). Inset shows in situ hybridization for SARS-CoV-2 with focal positive signal in hepatocytes (Advanced Cell Diagnostics, CA, USA). Follow-up biopsy (Panel B) shows similar features, although necroinflammatory foci (yellow arrow) were less prominent and individual apoptotic hepatocytes (white arrow) were more frequent (H&E 400X). The third biopsy (Panel C) showed entire lobules devoid of any apoptosis (H&E 200X). This biopsy did, however, show features of moderate acute cellular rejection, including mixed inflammation, portal venulitis, and reactive appearing bile ducts with lymphocytosis (green arrow), (Panel D; H&E 400X)

(Figure 3A) consisting of lymphocytes and apoptotic hepatocytes. Such foci were found in most lobules. A commercially available in-situ hybridization probe for SARS-CoV-2 (Advanced Cell Diagnostics, CA, USA), which is still being validated in liver tissue in our laboratory, showed focal positive signals in hepatocytes and rare inflammatory cells (Figure 3A inset). Intravenous methylprednisolone 5 mg/kg was administered cautiously given the histological interpretation with a weaning schedule as detailed in Table 1.

On POD 8, liver enzymes demonstrated minimal improvement. The infant exhibited transient increased work of breathing and nasal flaring that necessitated respiratory support with CPAP for 3-4 hours which resolved with frequent nasal suctioning. Diarrhea persisted and liver enzymes again increased on POD 9 despite recent steroid administration which led to the decision to discontinue MMF and to wean the steroids. Liver enzymes began to improve on POD 11. The patient again tested positive via nasopharyngeal SARS-CoV-2 PCR on POD 12. The viral load was unchanged from 8 days prior, with mean cycle threshold values of 19.8 and 19.9, respectively. Despite the persistent viral load, she remained afebrile through day 13 with steadily improving liver function tests and stable respiratory status on room air.

On POD 14, (10 days since SARS-CoV-2 diagnosis) she developed fevers. Repeat blood cultures were again negative and repeat chest radiograph showed persistent bilateral patchy

opacities without significant change from prior. She remained stable on room air, though required frequent nasal suctioning and defervesced after 4 hours. Her oxygenation was preserved throughout the episode.

On POD 16 (12 days since SARS-CoV-2 diagnosis), liver enzymes again worsened. Given that the time frame after transplant favored rejection and that her immunosuppression had been modified to allow immune reconstitution due to viral hepatitis, a second liver biopsy was performed on POD 17. Histology revealed broadly similar findings. There was a slight improvement in the acute cellular rejection (Banff 4), and the lobular hepatitis was characterized by more frequent individual apoptotic hepatocytes, though the necroinflammatory foci were still present (Figure 1B). The patient received human intravenous immune globulin (IVIG). Liver enzymes began trending down, until her discharge on POD 22.

As of POD 22, respiratory symptoms continued to improve and diarrhea that had previously persisted despite stopping MMF and magnesium supplements, was abating. The evolving clinical recovery picture was generally reflected by improving liver enzymes and resolution of respiratory symptoms and diarrhea. The team entertained using the mother as a potential source of convalescent serum<sup>7</sup> once enough time had elapsed (3-6 weeks) but given her persistent positive NP PCR for SARS-CoV-2 she could not donate and no other donor was available before patient recovery.

Follow-up evaluation in the outpatient clinic on POD 30 was notable for resolution of all symptoms including diarrhea, but liver enzymes were again elevated in the setting of a subtherapeutic tacrolimus trough (Table 1, Figure 2). A repeat liver biopsy was obtained. Histology demonstrated that the lobular apoptotic activity had largely resolved and was now absent to minimal (Figure 3C). Portal tracts were expanded by a mixed inflammatory infiltrate consisting of lymphocytes, histiocytes, and scattered eosinophils. Portal vein endotheliitis and mild to moderate bile duct injury in the majority of the portal tracts were noted. Essentially, these are the classical findings of ACR (Figure 3D). The diagnosis rendered was moderate ACR (Banff score  $6 = 2+2 + 2$ ) and resolved viral hepatitis.

The patient received a single intravenous bolus of methylprednisolone 10 mg/kg follow by an oral prednisolone recycle starting at 2 mg/kg/day. Tacrolimus dose was optimized, and MMF was restarted (15 mg/kg/dose BID). On POD 36 the patient remained clinically well, liver enzymes had improved and tacrolimus trough was at target.

The sequence of post-operative events, vital signs, and laboratory values are detailed in Table 1 and Figures 1 and 2.

### 3 | DISCUSSION

The respiratory manifestations of SARS-CoV-2 infection have received the most attention given the high mortality associated with acute respiratory distress syndrome (ARDS).<sup>1</sup> However, up to 60% of infected patients have elevated liver enzymes and these elevations appear higher in more severe cases.<sup>8</sup> The clinical manifestations of SARS-CoV-2 infection in children are generally thought to be mild,<sup>2</sup> but nothing previous to this case has been published regarding the clinical impact of the virus on liver allografts. We are reporting a novel case of SARS-CoV-2 infection in an infant manifested by transient respiratory distress, diarrhea, and significant hepatitis after LT and the details regarding her clinical course.

The clinical presentation in this case is quite different from previously reported patients with ARDS and transaminitis, as the post-LT hepatitis attributed to SARS-CoV-2 predominates. The relatively benign pulmonary disease exhibited by this patient aligns with the clinical presentation of other immunosuppressed subjects reported by D'Antiga et al<sup>3</sup> These observations support other anecdotal reports that selective immunosuppressants may mitigate the disease course and severity of patients with pulmonary SARS-CoV-2 infection, although the mortality rate in adult solid organ transplant recipients in our center appears to be higher than that in the general population.<sup>9</sup> The respiratory symptoms in this case are also similar to those reported in the largest pediatric series by Lu et al Like our case, the authors reported that 8.8% of their cases had diarrhea but did not include any specifics regarding hepatic biochemical profile.<sup>2</sup> The biochemical pattern in their report was primarily hepatitis supporting that the liver insult is mainly one of parenchymal injury. The main histological feature of moderate acute/lobular hepatitis, which was attributed to SARS-CoV-2, is different from the report

by Xu et al<sup>8</sup> The histological features we attributed to SARS-CoV-2 are similar to other acute viral hepatitis. We know by experience that in cases of a mixed histological picture with features of viral hepatitis and rejection, prevention of over-immunosuppression and eradication of infection has yielded the best outcomes. It is probable that the etiology of the observed fluctuations in liver enzymes was multifactorial. Though allograft rejection could have played a role in the patient's elevated enzymes, the histological changes of acute hepatitis and her overall improvement after immunosuppression reduction suggests that viral hepatitis played a predominant role early in the clinical course.

Since this infant and the donor were in close contact prior to transplantation and the SARS-CoV-2 PCR was not available for asymptomatic patients at the time of surgery, it is impossible to know when the recipient contracted the infection (either pre-LT or through the donated tissue). The possibility of nosocomial infection also exists as SARS-CoV-2 was quickly emerging in New York City during the time of the hospitalization and asymptomatic patients/family/health care workers could also have been disease vectors. There were intermittent common healthcare providers and family caretakers for both donor and recipient. However, post-transplant nosocomial infection seems less likely since donor and recipient were primarily cared for by two independent care teams in two separate hospital wards. SARS-CoV-2 infection was a rare occurrence in the pediatric hospital at the beginning of the hospitalization and both healthcare teams exercised universal health care precautions while providing care to both patients. We should all be aware of the epidemiological implications of conducting organ transplantation during this pandemic. This case underscores the importance of testing all donors (living or deceased) and recipients now that we have the capacity to do so rapidly and effectively before the transplant procedure, since many infected individuals may be asymptomatic, and supports the universal use of personal protective equipment while caring for this fragile population. The increased availability of rapid testing has prompted new institutional guidelines for performing SARS-CoV-2 PCR by NP swab of all patients within 24 hours of undergoing surgical procedures and proceeding only if negative. Patients with positive SARS-CoV-2 PCR with immediate life-threatening conditions will undergo surgery in a negative pressure room and maximum epidemiological control. This case would have been cancelled if either donor or recipient tested positive for SARS-CoV-2. One caveat is that the sensitivity and specificity of PCR testing may vary depending on the assay employed.<sup>10</sup> It is also unknown if persistent viral antigen shedding (positive NP PCR) has clinical or epidemiological significance for persistent infectivity/reactivation; this infant has remained SARS-CoV-2 PCR positive while asymptomatic. Antibody testing is a rapidly evolving technology that will potentially aid in the proper selection of donors and recipients. More longitudinal studies are needed to understand the immune relevance of the presence of antibodies. Antibody testing and quantification plays a pivotal role in determining post-infectious donor eligibility for convalescent plasma as means of passive immunity through the administration of viral-specific antibody. Given that this patient presented early

during the New York outbreak, not enough time had passed (usually 3-6 weeks) to find a suitable donor, our institution has developed all the regulatory and logistic work-flow to offer this therapeutic alternative. Finally, we want to share the off-label use of hydroxychloroquine in this age group without appreciable side effects, but of unproven efficacy. The role of IVIG has not been explored as a therapeutic option for SARS-CoV-2 infection especially in this case where IVIG available at that time would not be expected to have significant or any SARS-CoV-2 specific antibodies. This patient received IVIG to address low serum globulin levels and reports supporting the antimicrobial efficacy of IVIG in immunocompromised subjects.<sup>11</sup> The improvement of liver enzymes and diarrhea after its administration may have been coincidental.

#### 4 | CONCLUSIONS

This case highlights several important novel observations that have clinical and epidemiological implications. The first is the likelihood of a graft being infected by SARS-CoV-2, resulting in severe graft dysfunction manifested by acute viral hepatitis. The second is the lack of definite biochemical features differentiating the cause of graft injury. Finally, histologic evidence of both rejection and acute hepatitis may be observed, leading to challenges in treatment decision-making. Extrapolation from prior experience with other viral infections, and a favorable result in this case suggest that SARS-CoV-2 hepatitis in an allograft may be best addressed with decreased immunosuppression. Despite previous reports of the usually benign course of SARS-CoV-2 infection in children, this is certainly not true for all infected patients that merit prudent monitoring especially in the setting of solid organ transplantation. The medical community should remain cognizant of the potential downside of using investigational drugs outside investigational protocols. Limitations could include unknown drug-drug interactions, drug induced liver injury, unnecessary cost burden, and hampering the exploration of more promising alternatives options among others. Randomized trials are critical to establish the safety and efficacy of novel or currently available therapies that have been adopted based on anecdotal experience from adult literature and remain urgent during this global pandemic.

#### CONFLICT OF INTEREST

The authors have no conflict of interest related to this work.

#### ORCID

Adam Griesemer  <https://orcid.org/0000-0003-4894-2024>

Mercedes Martinez  <https://orcid.org/0000-0001-6128-0155>

#### REFERENCES

1. Guan WJ, Ni ZY, Hu Y, et al. Clinical characteristics of coronavirus disease 2019 in China. *N Engl J Med*. 2020;382(18):1708-1720.
2. Lu X, Zhang L, Du H, et al. SARS-CoV-2 infection in children. *N Engl J Med*. 2020;382:1663-1665.
3. D'Antiga L. Coronaviruses and immunosuppressed patients. The facts during the third epidemic. *Liver Transpl*. 2020;26:832-834.
4. Lagana SM, De Michele S, Lee MJ, et al. COVID-19 associated hepatitis complicating recent living donor liver transplantation. *Arch Pathol Lab Med*. 2020. <https://doi.org/10.5858/arpa.2020-0186-SA>.
5. USA COVID-19 cases on March 17th, 2020. online, 2020. <https://www.worldometers.info/coronavirus/country/us/>. Accessed May 1, 2020.
6. COVID-19 cases on New City on March 17th 2020; 2020. <https://www1.nyc.gov/site/doh/covid/covid-19-data-archive.page>. Accessed May 1, 2020.
7. Bloch EM, Shoham S, Casadevall A, et al. Deployment of convalescent plasma for the prevention and treatment of COVID-19. *J Clin Invest*. 2020;130(5):2757-2765.
8. Xu L, Liu J, Lu M, Yang D, Zheng X. Liver injury during highly pathogenic human coronavirus infections. *Liver Int*. 2020;40:998-1004.
9. Pereira MR, Mohan S, Cohen DJ, et al. COVID-19 in solid organ transplant recipients: initial report from the US epicenter. *Am J Transplant*. 2020. <https://doi.org/10.1111/ajt.15941>
10. Parcina M., Schneider U.V., Visseaux B., Jozic R., Hannel I., Lisby J.G.. Multicenter evaluation of the QIAstat Respiratory Panel-A new rapid highly multiplexed PCR based assay for diagnosis of acute respiratory tract infections. *PLoS One*. 2020;15:e0230183.
11. Shimizu M., Katoh H., Hamaoka S., et al. Protective effects of intravenous immunoglobulin and antimicrobial agents on acute pneumonia in leukopenic mice. *J Infect Chemother*. 2016;22:240-247.

**How to cite this article:** Heinz N, Griesemer A, Kinney J, et al.

A case of an Infant with SARS-CoV-2 hepatitis early after liver transplantation. *Pediatr Transplant*. 2020;00:e13778.

<https://doi.org/10.1111/petr.13778>